

Molar Incisor Hypomineralisation (MIH)



MI
Treatment
solutions
from GC

GC

Molar Incisor Hypomineralisation (MIH)

A global burden concerning one in seven children^{1,2}

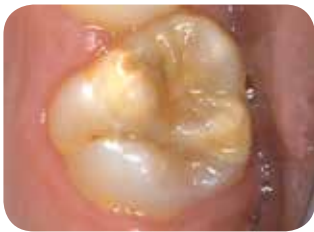MIH is a common **developmental condition** affecting primarily one or more first permanent molars. The central incisors may be affected as well, but this usually occurs to a lesser extent. Hypomineralisation of the second deciduous molars (HSPM) or canines may also occur.³ Children with HSPM are up to five times more likely to develop MIH in the permanent dentition.

Great varieties in severity exist, ranging from mild opacities to posteruptive enamel breakdown.

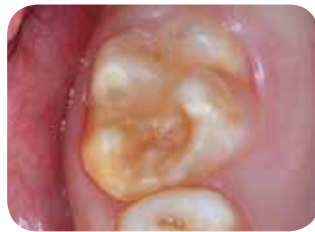Currently, the **aetiology** of MIH is still **unknown**. Some correlations with prenatal, perinatal and postnatal illness, exposure to antibiotics or chemicals such as dioxin, bisphenol A and polychlorinated biphenyl have been described, but sufficient evidence is still lacking.

Clinical appearance

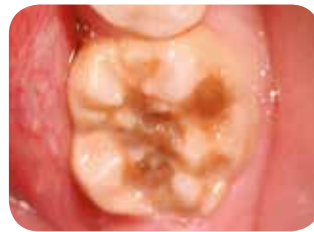- Demarcated opacities, ranging from creamy white to yellow, brown discolouration
- Defective enamel has normal thickness (unless posteruptive breakdown has occurred)
- Lesions may occur asymmetrically
- When a first molar is severely affected, there is an increased chance that the contralateral molar is also affected
- Lesions of central incisors are usually milder, but they can sometimes be unsightly



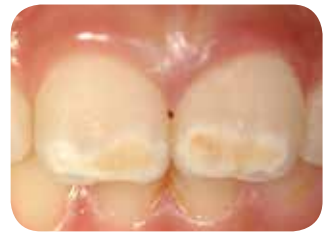Mild MIH
Courtesy of Prof. van Amerongen,
the Netherlands



Moderate MIH
Courtesy of Prof. Baroni, Italy



Severe MIH
Courtesy of Prof. Baroni, Italy



Affected incisors as part of MIH
Courtesy of Prof. Baroni, Italy

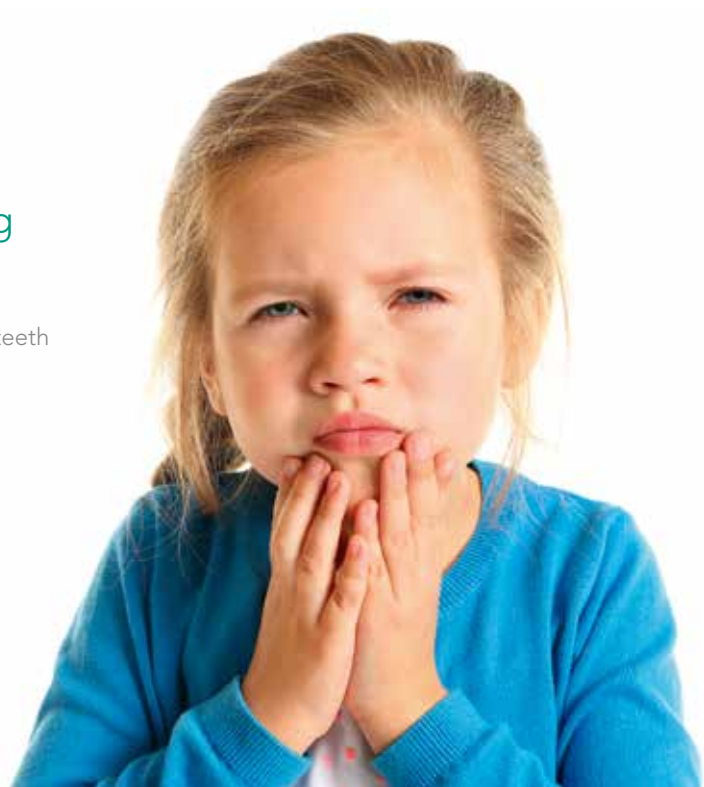Symptoms

- Hypersensitivity and decreased response to local anaesthesia
- Rapid caries progression
- Posteruptive breakdown

Clinical management of MIH is challenging due to:

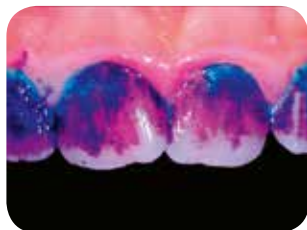
- Hypersensitivity and rapid development of dental caries in affected teeth
- Difficulty in achieving anaesthesia
- Limited cooperation of the young child
- Repeated marginal breakdown of restorations
- Often, an increased number of dental visits is required

Children with MIH often develop dental anxiety as a result of invasive and even painful dental experiences at a young age



Initial therapeutic intervention

Empowering your patient is the first step



Courtesy of Dr. Rouas, France

- The teeth should be brushed twice a day with a toothpaste containing at least 1000 ppm fluoride. Fluoride content should be age-appropriate; in older patients higher levels of fluoride may be desirable.
- Using identification tools such as **GC Tri Plaque ID Gel** can help to identify cariogenic plaque, motivate patients and give them the opportunity to optimise their brushing technique
- Frequent intake of sugar and acidic food should be avoided



Strengthen and desensitise with GC Tooth Mousse, GC MI Paste Plus and MI Varnish


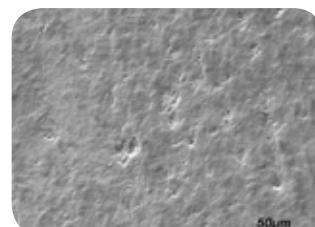
Topical treatments are useful to strengthen teeth and decrease sensitivity in MIH. The application of Recaldent (CPP-ACP), containing high levels of bio-available calcium and phosphate, has been shown to be effective in this case.^{4,5}

Tooth Mousse (without fluoride)/MI Paste Plus (900 ppm fluoride)

- Topical creme with Recaldent (CPP-ACP) for daily at home application
- Apply after brushing, before bedtime; do not rinse
- Provides extra protection for the teeth
- Neutralises acidic challenges

Tooth Mousse or MI Paste Plus?

Tooth Mousse and MI Paste Plus can be used for the same indications. Tooth Mousse is recommended below the age of 6 to avoid the risk of fluorosis and in cases where extra fluoride supplementation is not needed or desired. For overnight application, Tooth Mousse is recommended until the age of 12. MI Paste Plus can be used above that age.

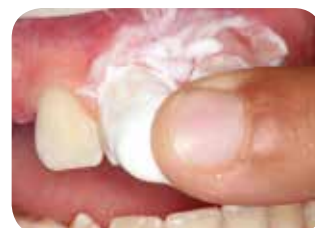

MI Paste Plus reduces porosity and improves homogeneity of hypomineralised enamel.
Courtesy of Dr. Crombie, Australia

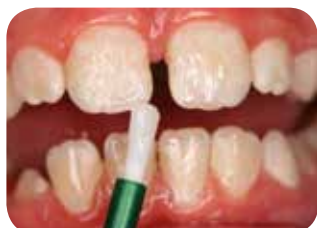MI Varnish (22600 ppm fluoride)

- Varnish with Recaldent (CPP-ACP) for quarterly in office application
- Apply after prophylactic cleaning
- Seals the dental tubules tightly; desensitises teeth and leaves a film of varnish on the surface

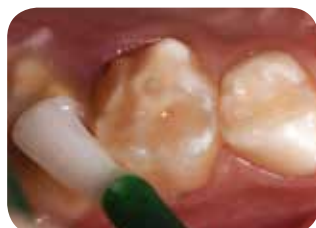Prior to use, carefully read the instructions for use.



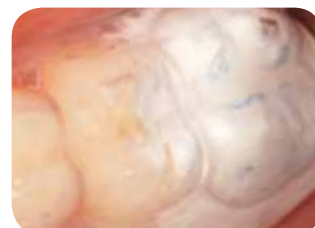Courtesy of Prof. Gatón Hernández, Spain



Courtesy of Dr. Marinova, Bulgaria



Courtesy of Dr. Rouas, France



Courtesy of Dr. Rouas, France

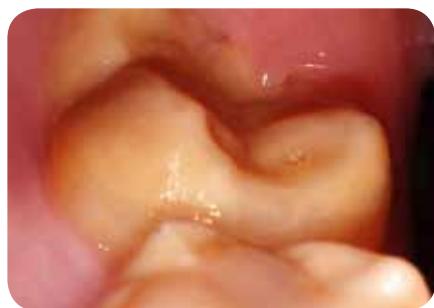Protect surfaces with **GC Fuji TRIAGE**

Fuji TRIAGE, a fluid glass ionomer, will help to protect the surface against caries formation and hypersensitivity

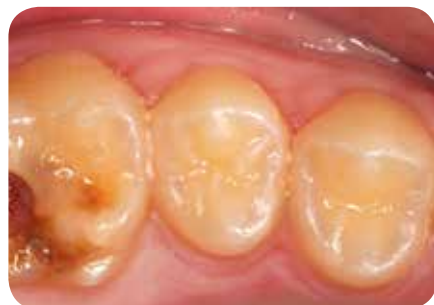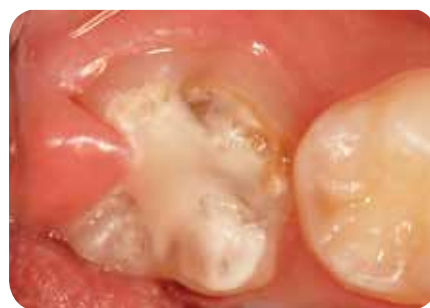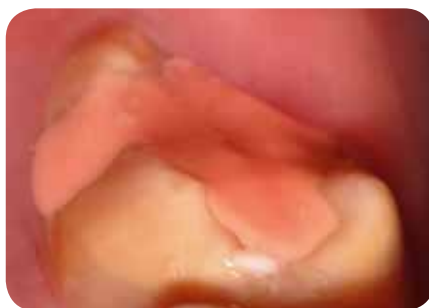- Fuji TRIAGE can bond chemically in a moist environment
- Teeth can be protected even before they are fully erupted
- The setting of Fuji TRIAGE, pink shade can be accelerated with the dental curing light

Early protection is important to avoid complications

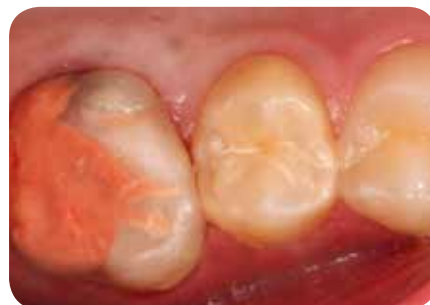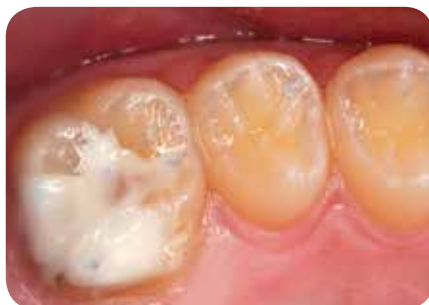- Fast and easy application; perfect for first-line treatment
- Helps to postpone or even avoid more invasive treatment options
- Since the procedure is generally well tolerated by children, the risk of developing dental anxiety is reduced



Courtesy of Dr. Rouas, France



Courtesy of Prof. Gatón Hernández, Spain



Courtesy of Prof. Gatón Hernández, Spain



Restorative treatment

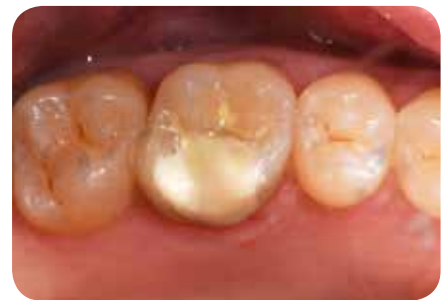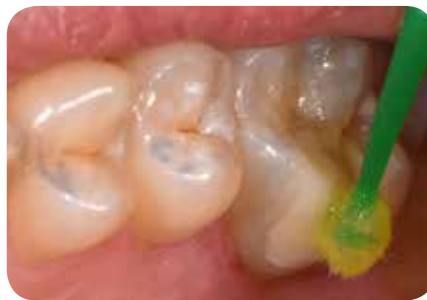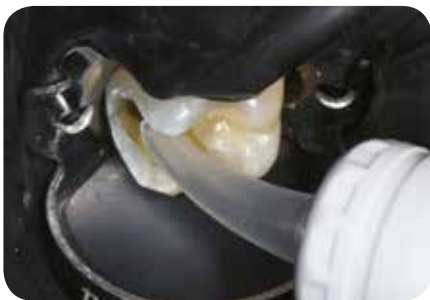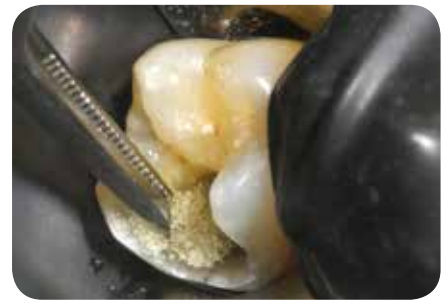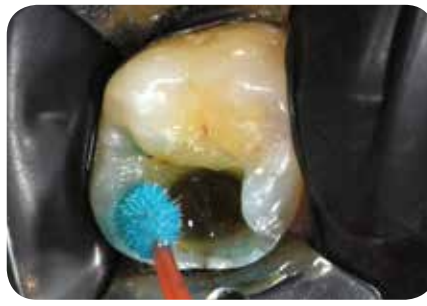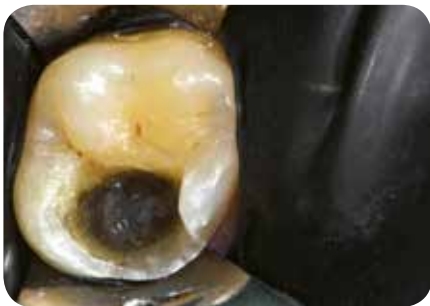Minimally Invasive restorations with **EQUIA Forte HT**

Long-term restorations

- The glass hybrid EQUIA Forte HT is suitable as a long-term, minimally invasive restorative. Moreover, its quick bulk placement is a huge advantage in young, anxious patients.
- The chemical adhesion and moisture tolerance of EQUIA Forte HT offer a great advantage since adhesion to hypomineralised enamel is challenging.
- In case teeth are difficult to anaesthetise, the Atraumatic Restorative Treatment (ART) approach can be used; caries is manually excavated before application of EQUIA Forte HT.⁶
- A composite can be placed when the lesions are very well demarcated and do not require too much additional removal of tooth tissue.

Interim therapeutic restorations

- In some cases of severe MIH, a definitive restoration cannot be placed immediately due to the young age. However, early treatment is necessary to stop and reverse the caries process.
- Glass ionomers or stainless steel crowns, luted with a glass ionomer cement, can then be indicated in awaiting of a definitive treatment, such as a composite or indirect restoration.



Courtesy of Dr. Rouas, France

Orthodontic considerations

In certain orthodontic conditions, it might be indicated to extract severely affected permanent first molars. The ideal moment is when the furcation of the second molar starts to calcify, usually around the age of 8,5-9 years. Extracting at that moment favours spontaneous migration of the second molar; results are usually better in the upper arch than in the lower arch.

Recall

Follow-up regimen adjusted to response to treatment

The recall frequency is usually higher for patients with MIH, due to the higher caries susceptibility. Several points have to be kept in mind:

- Restorations need to be controlled regularly, as adhesion to hypomineralised enamel is challenging
- It is important to maintain the patient's compliance to home treatment and to evaluate its effects regularly
- Oral hygiene (with Tri Plaque ID Gel) and dietary habits should be regularly evaluated
- Interim therapeutic restorations need to be monitored and replaced when the circumstances have become appropriate for definitive treatment

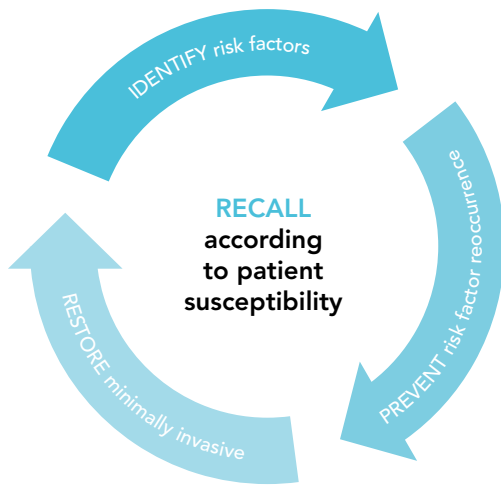
An important part of the preventive strategy is the home care. It is crucial to motivate and educate the child/caregiver because they are the ones who will have to implement good oral hygiene habits and healthy dietary intake.

The Dentonauts program further puts the emphasis on making every dental visit a positive experience for the child. This is important to ensure the compliance in the long term and to ensure life-long, healthy functioning.



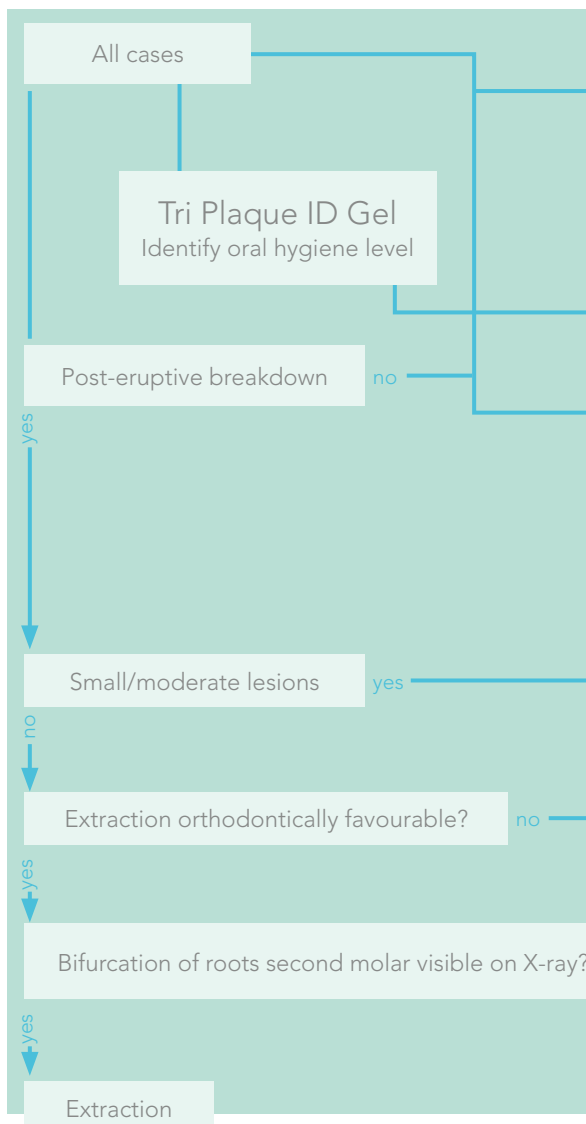
Minimum Intervention Treatment Plan for MIH

A framework for patient-centred treatment

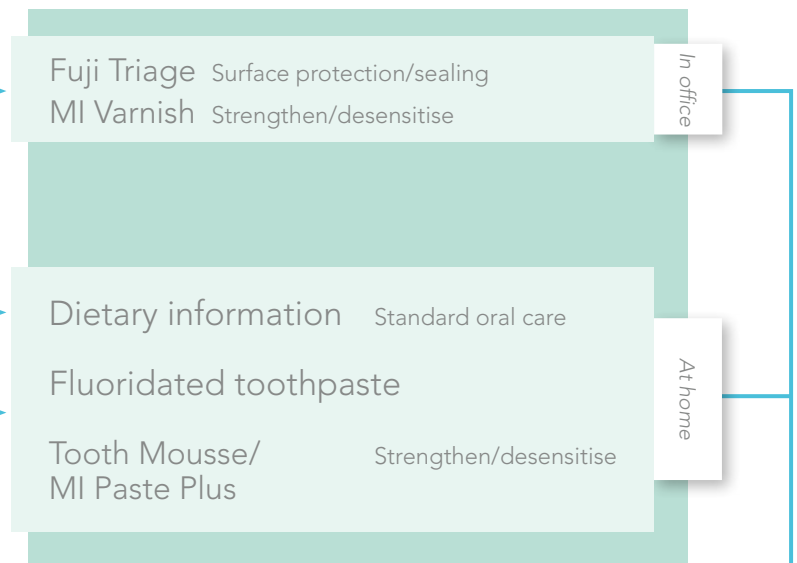

It is essential to adapt the treatment of MIH to the individual patient's conditions. The schedule below will make it easier to select the necessary interventions. It also shows which products from GC are especially suited for each individualised treatment plan.

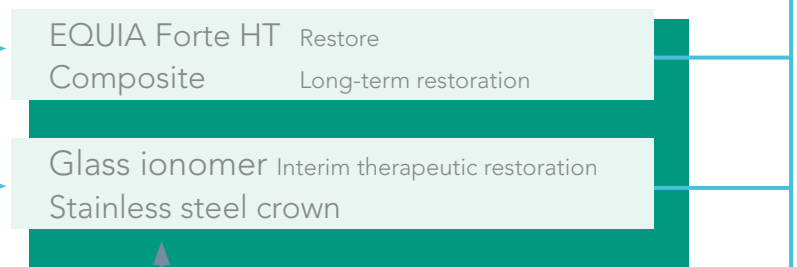IDENTIFY



PREVENT



RESTORE



RECALL





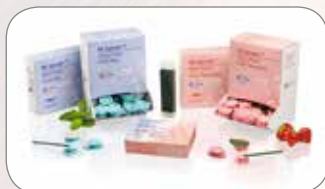GC Tri Plaque ID Gel, tubes of 40 g (36 ml)	
004273	GC Tri Plaque ID Gel, 1 x 40g (36ml)



GC Tooth Mousse, tubes of 40 g (35 ml)					
GC Tooth Mousse Assorted packs					
890102	Box of 5 tubes, assorted (1 of each flavour) (Melon, Strawberry, Tutti-Frutti, Mint, Vanilla)				
462032	Box of 10 Tubes, assorted (two of each flavour) (Melon, Strawberry, Tutti-Frutti, Mint, Vanilla)				
GC Tooth Mousse, 10-Pack of a single flavour					
462520	Strawberry	462522	Mint	462270	Vanilla
462521	Melon	462523	Tutti-Frutti		



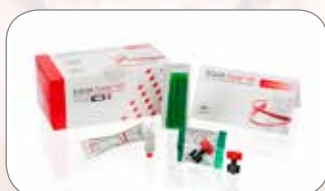GC MI Paste Plus, tubes of 40 g (35 ml)					
GC MI Paste Plus Assorted packs					
900441	Box of 5 tubes, assorted (1 of each flavour) (Melon, Strawberry, Tutti-Frutti, Mint, Vanilla)				
462614	Box of 10 tubes, assorted (two of each flavour) (Melon, Strawberry, Tutti-Frutti, Mint, Vanilla)				
GC MI Paste Plus, 10-Pack of a single flavour					
462621	Mint	462887	Melon	462889	Tutti-Frutti
462886	Strawberry	462888	Vanilla		



MI Varnish unit doses of 0.40 ml			
MI Varnish Intro pack			
900746	MI Varnish Intro pack, 10 unit doses MI Varnish (5 Strawberry + 5 Mint), and 20 brushes		
MI Varnish Refill pack; 35 unit doses with brushes			
900747	Strawberry	900748	Mint
MI Varnish Clinic pack; 100 unit doses with brushes			
900749	Strawberry	900750	Mint



GC Fuji TRIAGE CAPS (mixed volume per capsule 0.13 ml)			
Refill: box of 50 capsules, mixed volume per capsule 0.13 ml			
002495	Pink	002496	White
GC Fuji TRIAGE Powder/Liquid			
1-1 pack: 15 g powder, 10 g liquid, 6 g Dentin Conditioner & accessories			
002490	Pink	002491	White



EQUIA Forte HT CAPS (mixed volume per capsule 0.14 ml)					
Intro pack: box with 20 capsules of EQUIA Forte HT Fil, 20 unit doses of EQUIA Forte HT Coat & disposable brushes					
901574	A2	901575	A3	901576	B2
Promo Pack: 2 boxes with 50 capsules EQUIA Forte HT Fil, 4 ml EQUIA Forte Coat & disposable brushes					
901577	A2 (x2)		901579	A3 (x2)	
901578	A2-A3		901580	B2-A3	

Other packages are also available; for further information, check our online catalogue.

GC Tri Plaque ID Gel, GC Tooth Mousse, GC MI Paste Plus, MI Varnish, GC Fuji Triage and EQUIA Forte HT are trademarks from GC.



Check out the webinar: „Hypomineralised enamel (MIH) coming to a child near you!“ by Prof. David Manton, Melbourne Dental School, Australia.

GC EUROPE N.V.

Head Office
Researchpark
Haasrode-Leuven 1240
Interleuvenlaan 33
B-3001 Leuven
Tel. +32.16.74.10.00
Fax. +32.16.40.48.32
info@gceurope.dental
http://www.gceurope.com

GC UNITED KINGDOM Ltd.

Coopers Court
Newport Pagnell
UK-Bucks. MK16 8JS
Tel. +44.1908.218.999
Fax. +44.1908.218.900
info@uk.gceurope.dental
http://uk.gceurope.com

- Schwendicke F, Elhennawy K., Reda S., Bekes K., Manton DJ., Krois J. Global burden of molar incisor hypomineralization. J Dent, 2018; 68: 10–18.
- Zhao D., Dong B., Yu D., Ren Q. & Sun Y. The prevalence of molar incisor hypomineralization: evidence from 70 studies. Int J Paediatr Dent, 2018; 28: 170-179.
- Garot E., Denis A., Delbos Y., Manton D., Silva M., Rouas P. Are hypomineralised lesions on second primary molars (HSPM) a predictive sign of molar incisor hypomineralisation (MIH)? A systematic review and a meta-analysis. J Dent 2018;72:8-13.
- Baroni, C. & Marchionni, S. MIH supplementation strategies: Prospective clinical and laboratory trial. J. Dent. Res, 2011;90: 371–376.
- Wierichs, R. J., Stausberg, S., Lausch, J., Meyer-Lueckel, H. & Esteves-Oliveira, M. Caries-Preventive Effect of NaF, NaF plus TCP, NaF plus CPP-ACP, and SDF Varnishes on Sound Dentin and Artificial Dentin Caries in vitro. Caries Res, 2018; 52: 199–211.
- Grossi JA, Cabral RN, Ribeiro APD, Leal SC. Glass hybrid restorations as an alternative for restoring hypomineralized molars in the ART model. BMC Oral Health, 2018; 18;18(1):65.